

ORIGINAL ARTICLE

Pegaptanib for Neovascular Age-Related Macular Degeneration

Evangelos S. Gragoudas, M.D., Anthony P. Adamis, M.D.,
Emmett T. Cunningham, Jr., M.D., Ph.D., M.P.H., Matthew Feinsod, M.D.,
and David R. Guyer, M.D., for the VEGF Inhibition Study
in Ocular Neovascularization Clinical Trial Group

ABSTRACT

BACKGROUND

Pegaptanib, an anti-vascular endothelial growth factor therapy, was evaluated in the treatment of neovascular age-related macular degeneration.

METHODS

We conducted two concurrent, prospective, randomized, double-blind, multicenter, dose-ranging, controlled clinical trials using broad entry criteria. Intravitreal injection into one eye per patient of pegaptanib (at a dose of 0.3 mg, 1.0 mg, or 3.0 mg) or sham injections were administered every 6 weeks over a period of 48 weeks. The primary end point was the proportion of patients who had lost fewer than 15 letters of visual acuity at 54 weeks.

RESULTS

In the combined analysis of the primary end point (for a total of 1186 patients), efficacy was demonstrated, without a dose-response relationship, for all three doses of pegaptanib ($P < 0.001$ for the comparison of 0.3 mg with sham injection; $P < 0.001$ for the comparison of 1.0 mg with sham injection; and $P = 0.03$ for the comparison of 3.0 mg with sham injection). In the group given pegaptanib at 0.3 mg, 70 percent of patients lost fewer than 15 letters of visual acuity, as compared with 55 percent among the controls ($P < 0.001$). The risk of severe loss of visual acuity (loss of 30 letters or more) was reduced from 22 percent in the sham-injection group to 10 percent in the group receiving 0.3 mg of pegaptanib ($P < 0.001$). More patients receiving pegaptanib (0.3 mg), as compared with sham injection, maintained their visual acuity or gained acuity (33 percent vs. 23 percent; $P = 0.003$). As early as six weeks after beginning therapy with the study drug, and at all subsequent points, the mean visual acuity among patients receiving 0.3 mg of pegaptanib was better than in those receiving sham injections ($P < 0.002$). Among the adverse events that occurred, endophthalmitis (in 1.3 percent of patients), traumatic injury to the lens (in 0.7 percent), and retinal detachment (in 0.6 percent) were the most serious and required vigilance. These events were associated with a severe loss of visual acuity in 0.1 percent of patients.

CONCLUSIONS

Pegaptanib appears to be an effective therapy for neovascular age-related macular degeneration. Its long-term safety is not known.

From the Massachusetts Eye and Ear Infirmary, Boston (E.S.G.); and Eyetech Pharmaceuticals, New York (A.P.A., E.T.C., M.F., D.R.G.). Address reprint requests to Dr. Gragoudas at the Retina Service, Massachusetts Eye and Ear Infirmary and Harvard Medical School, 243 Charles St., Boston, MA 02114, or at evangelos_gragoudas@meei.harvard.edu.

N Engl J Med 2004;351:2805-16.

Copyright © 2004 Massachusetts Medical Society.

THE USE OF A SPECIFIC ANTAGONIST OF an angiogenic factor as a strategy to treat disease was proposed in the *Journal* more than 30 years ago.¹ Since that time, extensive evidence has suggested a causal role of vascular endothelial growth factor (VEGF) in several diseases of the human eye in which neovascularization and increased vascular permeability occur.¹⁻¹² In humans, ocular VEGF levels have been shown to rise synchronously with and in proportion to the growth and leakage of new vessels.²⁻⁴ Animal models of corneal,⁵ iridic,⁶ retinal,⁷ and choroidal⁸ neovascularization have shown that neovascularization is dependent on the presence of VEGF. In a complementary fashion, the introduction of VEGF into normal animal eyes resulted in a recapitulation of the pathologic neovascularization that occurs in these tissues during disease.⁹⁻¹² Taken together, these data provided a strong rationale for the targeting of VEGF in human disorders that manifest as ocular neovascularization and increased vascular permeability.

Age-related macular degeneration is the leading cause of irreversible, severe loss of vision in people 55 years of age and older in the developed world, and it remains an area of unmet medical need.¹³ The neovascular form of the disease represents approximately 10 percent of the overall disease prevalence, but it is responsible for 90 percent of the severe vision loss.¹⁴ It is expected to develop in almost 1 million people over the age of 55 years in the United States within the next five years, making it a major public health issue in an increasing population of older persons.¹⁵

Neovascular age-related macular degeneration is characterized by choroidal neovascularization that invades the subretinal space, often leading to exudation and hemorrhage. If the condition is left untreated, damage to photoreceptors and loss of central vision usually result, and after several months to years, the vessels are largely replaced by a fibrovascular scar.¹⁶⁻¹⁸ Patients in whom a central scotoma develops have difficulty performing critical tasks that are typically associated with central vision, such as reading, driving, walking, and recognizing faces, and the difficulty has a major effect on their quality of life.¹⁹

With greater understanding of the pathogenesis of neovascular age-related macular degeneration, drug therapies targeted at the causal molecular mechanisms have been advanced. Pegaptanib (Macugen), a 28-base ribonucleic acid aptamer (from the Latin *aptus*, to fit; and the Greek *meros*, part or

region) covalently linked to two branched 20-kD polyethylene glycol moieties, was developed to bind and block the activity of extracellular VEGF, specifically the 165-amino-acid isoform (VEGF₁₆₅). Aptamers characteristically bind with high specificity and affinity to target molecules, including proteins. The binding relies on the specific three-dimensional conformation of the properly folded aptamer. To prolong activity at the site of action, the sugar backbone of pegaptanib was modified to prevent degradation by endogenous endonucleases and exonucleases, and the polyethylene glycol moieties were added to increase the half-life of the drug in the vitreous.²⁰

We hypothesized that the targeting of VEGF₁₆₅ would affect the underlying conditions common to all forms of choroidal neovascularization, including the three angiographic subtypes of neovascular age-related macular degeneration. We conducted two concurrent clinical trials to test the short-term safety and effectiveness of pegaptanib in patients with a broad spectrum of visual acuities, lesion sizes, and angiographic subtypes of lesions at baseline.

METHODS

STUDY DESIGN

We conducted two concurrent, prospective, randomized, double-blind, multicenter, dose-ranging, controlled clinical trials at 117 sites in the United States, Canada, Europe, Israel, Australia, and South America in our study. Patients were eligible for inclusion if they were 50 years of age or older and had subfoveal sites of choroidal neovascularization secondary to age-related macular degeneration and a range of best corrected visual acuity of 20/40 to 20/320 in the study eye and of 20/800 or better in the other eye.

The angiographic subtype of a patient's lesion was defined in relation to the visualization of choroidal new vessels (classic) in the fluorescein angiogram. The total area of a predominantly classic lesion includes more than 50 percent classic choroidal neovascularization, the total area of a minimally classic lesion includes less than 50 percent classic choroidal neovascularization, and the total area of an occult lesion includes no classic choroidal neovascularization. The total size of a lesion, choroidal neovascularization, or leakage was measured on a frame on the fluorescein angiogram with the optic-disk area as the unit of measure; it is equal to 2.54 mm². The size of a lesion, choroidal

neovascularization, or leakage is expressed as multiples of this standard optic-disk area.

Patients with all angiographic subtypes of lesions were enrolled, and lesions with a total size up to and including 12 optic-disk areas (including blood, scar or atrophy, and neovascularization) were permitted. Details of the method are provided in the Supplementary Appendix, available with the full text of this article at www.nejm.org.

TREATMENT AND OUTCOMES

Patients were randomly assigned to receive either sham injection or intravitreal injection of pegaptanib (Macugen, Eyetech Pharmaceuticals) into one eye every 6 weeks over a period of 48 weeks, for a total of nine treatments. To maintain masking of the patients, the patients receiving sham injections and those receiving the study medication were treated identically, with the exception of scleral penetration. All patients (including those receiving sham injection) underwent an ocular antisepsis procedure and received injected subconjunctival anesthetic. The patients receiving sham injections had an identical syringe — but without a needle — pressed against the eye wall to mimic the active doses that were injected through the pars plana into the vitreous cavity. The injection technique precluded the patient from seeing the syringe. To maintain masking of the investigators, the study ophthalmologist responsible for patient care and for the assessments did not administer the injection. In all cases, a separate, certified visual-acuity examiner masked to the treatment assignment and to previous measurements of visual acuity assessed distance visual acuity.

Owing to ethical considerations, the use of photodynamic therapy with verteporfin was permitted only in the treatment of patients with predominantly classic lesions, as defined in the product label approved by the Food and Drug Administration, and at the discretion of the ophthalmologist, who was masked as to the treatment assignment. The prespecified primary end point for efficacy was the proportion of patients who lost fewer than 15 letters of visual acuity (defined as three lines on the study eye chart) between baseline and week 54.

The trials were designed by the steering committee of the VEGF [Vascular Endothelial Growth Factor] Inhibition Study in Ocular Neovascularization Clinical Trial Group. The data were held and analyzed by the data management and statistics group. The manuscript was prepared by the writing

committee. Dr. Gragoudas chaired the writing committee, served as the outside academic investigator vouching for the veracity and completeness of the data analyses, had access to the full data set, and was responsible for the decision to submit the manuscript for publication.

RESULTS

One trial included 586 patients at 58 sites in the United States and Canada and was conducted from August 2001 through July 2002; the other trial included 622 patients at 59 other sites worldwide and was conducted from October 2001 through August 2002. Of the 1208 patients randomly assigned to treatment in the two studies (297 patients assigned to receive 0.3 mg of pegaptanib; 305 patients, 1.0 mg of pegaptanib; 302 patients, 3.0 mg of pegaptanib; and 304 patients, sham injections), 1190 received at least one study treatment (295 patients received 0.3 mg of pegaptanib; 301 patients, 1.0 mg of pegaptanib; 296 patients, 3.0 mg of pegaptanib; and 298 patients, sham injections). The demographic and ocular characteristics of the patients at baseline were similar among the treatment groups (Table 1).

Four patients were not included in the efficacy analyses, because a sufficiently standardized assessment of visual acuity was not completed at baseline. Therefore, a total of 1186 patients received at least one study treatment, had visual acuity assessments at baseline, and were included in efficacy analyses (294 patients who received 0.3 mg of pegaptanib; 300 patients, 1.0 mg of pegaptanib; 296 patients, 3.0 mg of pegaptanib; and 296 patients, sham injections). A total of 7545 intravitreal injections of pegaptanib and 2557 sham injections were administered. Approximately 90 percent of the patients in each treatment group completed the study. In all the treatment groups, an average of 8.5 injections were administered per patient out of a possible total of 9 injections.

The general health status of the patients entering the trial, calculated for all patients receiving pegaptanib as compared with those receiving sham injection, was as follows: hypertension (55 percent in the pegaptanib groups vs. 48 percent in the sham-injection group), hypercholesterolemia (21 percent vs. 18 percent), diabetes mellitus (10 percent vs. 7 percent), cardiac disorders (35 percent vs. 34 percent), cerebrovascular disease (3 percent vs. 1 percent), peripheral arterial disease (3 percent vs.

Table 1. Demographic and Ocular Characteristics of Patients at Baseline.*

Characteristic	0.3 mg Pegaptanib (N=295)	1.0 mg Pegaptanib (N=301)	3.0 mg Pegaptanib (N=296)	Sham Injection (N=298)
Sex — no. (%)				
Male	133 (45)	136 (45)	105 (35)	120 (40)
Female	162 (55)	165 (55)	191 (65)	178 (60)
Race — no. (%)†				
White	283 (96)	291 (97)	286 (97)	284 (95)
Other	12 (4)	10 (3)	10 (3)	14 (5)
Age — no. (%)				
50–64 yr	19 (6)	21 (7)	18 (6)	21 (7)
65–74 yr	86 (29)	105 (35)	90 (30)	94 (32)
75–84 yr	155 (53)	147 (49)	153 (52)	160 (54)
≥85 yr	35 (12)	28 (9)	35 (12)	23 (8)
Angiographic subtype of lesion — no. (%)‡				
Predominantly classic	72 (24)	78 (26)	80 (27)	76 (26)
Minimally classic	111 (38)	108 (35)	105 (35)	102 (34)
Occult with no classic	112 (38)	115 (38)	111 (38)	120 (40)
Size of lesion§	3.7±2.4	4.0±2.4	3.7±2.5	4.2±2.8
History of ocular surgery or laser treatment — no. (%)	123 (42)	117 (39)	124 (42)	124 (42)
Visual acuity				
Study eye				
Mean	52.8±12.6	50.7±12.8	51.1±12.9	52.7±13.0
Median (range)	55 (11–75)	52 (19–77)	53 (14–76)	53 (11–77)
Other eye				
Mean	56.2±27.2	54.8±27.6	56±26.4	55.9±27.0
Median (range)	68 (3–85)	67 (3–85)	65 (4–85)	67 (2–85)

* Plus-minus values are means ±SD.

† Race was determined by the treating investigators.

‡ In relation to the visualization of choroidal new vessels (classic) in the fluorescein angiogram, a predominantly classic lesion includes 50 percent or more classic choroidal neovascularization, a minimally classic lesion includes less than 50 percent classic choroidal neovascularization, and an occult lesion includes no classic choroidal neovascularization.

§ The size of lesions was measured as the number of optic-disk areas (including blood scar or atrophy and neovascularization), each of which is 2.54 mm².

3 percent), and electrocardiographic abnormalities (53 percent vs. 48 percent).

In the combined analysis, all three doses of pegaptanib differed significantly from the sham injection in terms of the prespecified primary efficacy end point (Table 2). A loss of fewer than 15 letters of visual acuity was observed at week 54 in 206 (70 percent) of 294 patients assigned to receive 0.3 mg of pegaptanib ($P<0.001$), 213 (71 percent) of 300 patients assigned to 1.0 mg of pegaptanib ($P<0.001$), and 193 (65 percent) of 296 patients assigned to 3.0 mg of pegaptanib ($P=0.03$), as compared with

164 (55 percent) of 296 patients assigned to receive sham injection. Similar results were obtained when the analyses were restricted to the subgroup of patients who were evaluated both at baseline and at week 54 (accounting for 92 percent of those receiving 0.3 mg of pegaptanib, 92 percent of those receiving 1.0 mg of the drug, 89 percent of those receiving 3.0 mg of the drug, and 93 percent of those receiving sham injections); the similar findings indicate that missing data probably did not influence the results. In this population at week 54, a loss of fewer than 15 letters was observed in 192 (71 percent) of

Table 2. Rate of Visual-Acuity Loss, Measured as the Loss of Fewer Than 15 Letters, in 1186 Patients.*

Time	0.3 mg Pegaptanib (N=294)		1.0 mg Pegaptanib (N=300)		3.0 mg Pegaptanib (N=296)		Sham Injection (N=296)
	No. (%)	P Value vs. Sham Injection	No. (%)	P Value vs. Sham Injection	No. (%)	P Value vs. Sham Injection	No. (%)
Week 12	256 (87)	0.01	259 (86)	0.04	251 (85)	0.13	237 (80)
Week 24	242 (82)	<0.001	239 (80)	<0.001	224 (76)	0.003	190 (64)
Week 36	220 (75)	<0.001	229 (76)	<0.001	222 (75)	<0.001	175 (59)
Week 54	206 (70)	<0.001	213 (71)	<0.001	193 (65)	0.03	164 (55)

* The differences between the doses of pegaptanib were not significant.

271 patients assigned to receive 0.3 mg of pegaptanib ($P<0.001$), 198 (72 percent) of 275 patients assigned to 1.0 mg of the study drug ($P<0.001$), and 166 (63 percent) of 264 patients assigned to 3.0 mg of pegaptanib ($P=0.14$), as compared with 154 (56 percent) of 275 patients assigned to sham injection. There was no evidence in any of the analyses that pegaptanib at 1.0 mg or 3.0 mg was more effective than at 0.3 mg. The results of the two trials were similar, with both reaching statistical significance for the primary efficacy end point (0.3 mg of pegaptanib, $P=0.03$ and $P=0.01$).

The outcomes for the secondary end points were consistent with those for the primary end point. A greater proportion of the patients treated with pegaptanib maintained or gained visual acuity (that is, they had no change in the number of letters or a gain of one or more letters). For the combined analysis, 33 percent of patients receiving 0.3 mg of pegaptanib ($P=0.003$), 37 percent of those receiving 1.0 mg ($P<0.001$), and 31 percent of those receiving 3.0 mg ($P=0.02$) maintained vision or gained vision as compared with 23 percent of those receiving sham injection. At week 54, larger proportions of patients receiving pegaptanib, as compared with those receiving sham injection, also gained 5, 10, or 15 letters of visual acuity (approximately equivalent to one, two, and three lines on the study eye chart, respectively) (Table 3).

Patients in the sham-injection group were twice as likely to have a severe loss of vision (i.e., a loss of 30 letters or more or six lines on the study eye chart) as patients receiving pegaptanib at 0.3 mg (22 percent vs. 10 percent, $P<0.001$) or 1.0 mg (22 percent vs. 8 percent, $P<0.001$). Among patients receiving a dose of 3.0 mg, 14 percent had severe vision loss

($P=0.01$ for the comparison with the sham-injection group) (Table 3).

A smaller percentage of patients receiving pegaptanib had a Snellen equivalent visual acuity of 20/200 or worse, or legal blindness, in the study eye at week 54 than of those in the sham-injection group (pegaptanib at 0.3 mg, 38 percent; 1.0 mg, 43 percent; 3.0 mg, 44 percent; sham injection, 56 percent; $P<0.001$ for the comparison between all treatment groups and the sham-injection group) (Table 3).

The effectiveness of pegaptanib was evident as early as the first study visit after the treatment was started (week 6), and it increased over time up to week 54, as measured by the mean loss of visual acuity from baseline to each study visit as compared with that in the sham-injection group ($P<0.002$ at every point for a dose of pegaptanib at 0.3 mg or 1.0 mg, and $P<0.05$ at every point for a dose of 3.0 mg) (Fig. 1A).

There was no evidence that any angiographic subtype of the lesion, the size of the lesion, or the level of visual acuity at baseline precluded a treatment benefit. For those receiving pegaptanib at 0.3 mg, a treatment benefit was observed among all patients with all angiographic subtypes of lesions ($P<0.03$ for each subtype) (Fig. 1B), baseline levels of visual acuity (<54 or ≥ 54 letters, $P<0.01$ for each group) (Fig. 1C), and lesion sizes at baseline (<4 or ≥ 4 optic-disk areas, $P<0.02$ for each group) (Fig. 1D). Numerically superior outcomes were observed among patients with different subtypes of lesions treated with pegaptanib at 1.0 mg and 3.0 mg as well (Fig. 1B). The results of multiple logistic-regression analyses revealed that no factor other than assignment to treatment with pegaptanib was

Table 3. Maintenance, Gain, and Severe Loss of Visual Acuity with Pegaptanib and Sham Injection.*

End Points	0.3 mg Pegaptanib (N=294)	1.0 mg Pegaptanib (N=300)	3.0 mg Pegaptanib (N=296)	Sham Injection (N=296)
Maintenance or gain ≥ 0 letters — no. (%)	98 (33)	110 (37)	93 (31)	67 (23)
P value vs. sham injection	0.003	<0.001	0.02	
Gain ≥ 5 letters — no. (%)	64 (22)	69 (23)	49 (17)	36 (12)
P value vs. sham injection	0.004	0.002	0.12	
Gain ≥ 10 letters — no. (%)	33 (11)	43 (14)	31 (10)	17 (6)
P value vs. sham injection	0.02	0.001	0.03	
Gain ≥ 15 letters — no. (%)	18 (6)	20 (7)	13 (4)	6 (2)
P value vs. sham injection	0.04	0.02	0.16	
Loss ≥ 30 letters — no. (%)	28 (10)	24 (8)	40 (14)	65 (22)
P value vs. sham injection	<0.001	<0.001	0.01	
Visual acuity in study eye $\leq 20/200$ (legal blindness) — no. (%)	111 (38)	128 (43)	129 (44)	165 (56)
P value vs. sham injection	<0.001	<0.001	0.001	

* Where data were missing, the last-observation-carried-forward method was used. P values were calculated with the use of the Cochran–Mantel–Haenszel test. Loss of 30 or more letters was defined as severe loss of visual acuity.

significantly associated with this response (0.3-mg dose, $P < 0.001$).

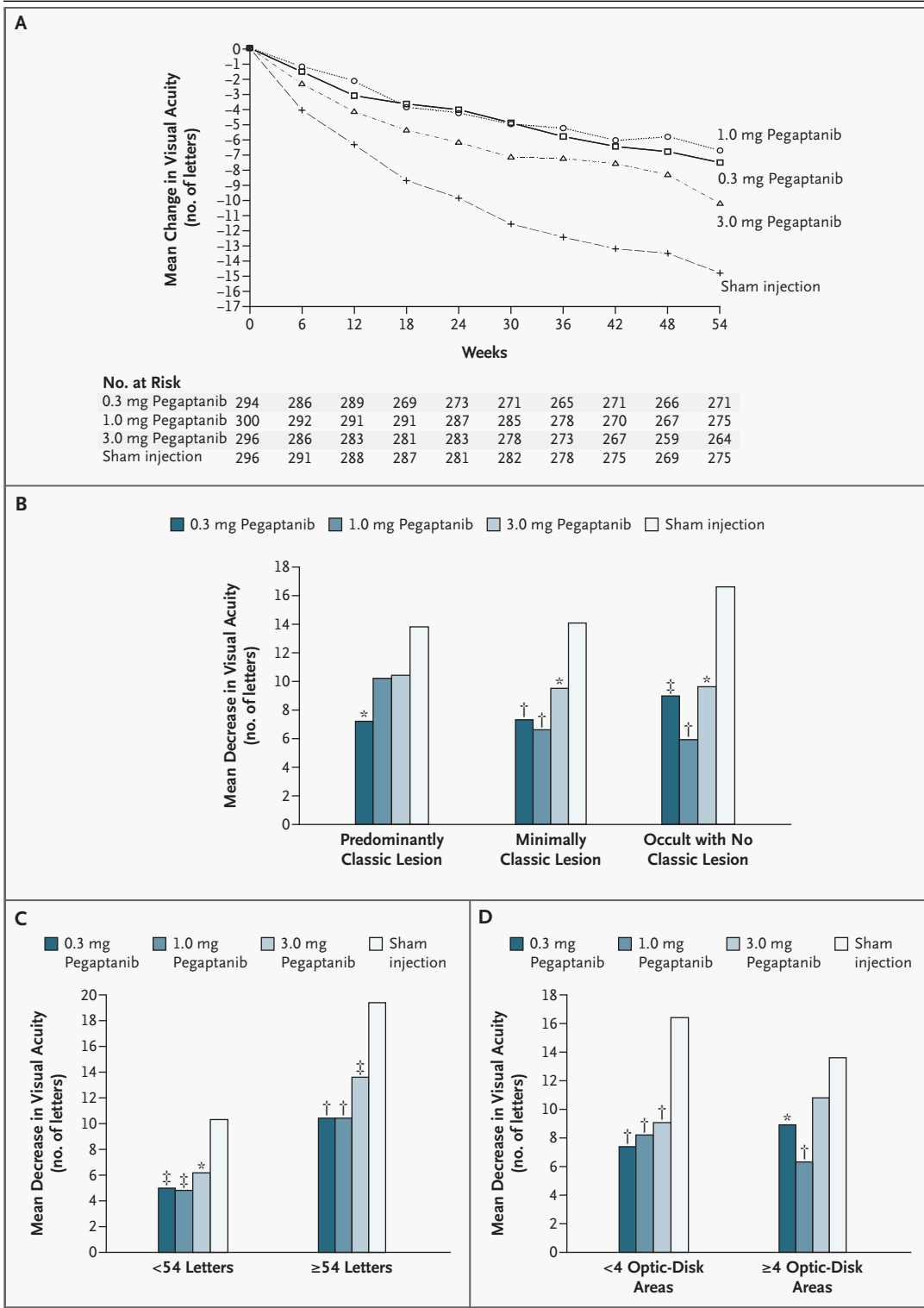
The majority (78 percent) of the study patients never received photodynamic therapy while in the study (at or after the baseline evaluation), and 75 percent of the patients never received photodynamic therapy at any time (i.e., they had no history of photodynamic therapy, nor did they receive the treatment during the study) in the study eye. The rate of use of this therapy before enrollment and at baseline was similar among the treatment groups; therapy before enrollment was used for stratification at randomization. A history of photodynamic therapy was reported at baseline by 24 patients receiving pegaptanib at 0.3 mg (8 percent), 29 patients receiving 1.0 mg (10 percent), 27 patients receiving 3.0 mg (9 percent), and 18 patients receiving sham injections (6 percent).

The study investigators administered photodynamic therapy at baseline to 36 patients receiving 0.3 mg of pegaptanib (12 percent), 31 patients receiving 1.0 mg (10 percent), 38 patients receiving 3.0 mg (13 percent), and 40 patients receiving sham injections (13 percent). A slightly higher proportion of patients receiving sham injections than those receiving pegaptanib received photodynamic therapy after baseline, suggesting a possible bias against pegaptanib. After baseline, photodynamic therapy was administered to 49 patients receiving 0.3 mg of pegaptanib (17 percent), 55 patients receiving

1.0 mg (18 percent), 57 patients receiving 3.0 mg (19 percent), and 62 patients receiving sham injections (21 percent). Therefore, the treatment benefit of pegaptanib was present despite the higher rate

Figure 1 (facing page). Mean Change in Scores for Visual Acuity.

Panel A shows the mean changes in visual acuity from baseline to week 54 ($P < 0.002$ at every point for the comparison of 0.3 mg or 1.0 mg of pegaptanib with sham injection at week 54, and $P < 0.05$ at every point for the comparison of 3.0 mg of pegaptanib with sham injection at all other points after baseline). Panels B, C, and D show the mean changes in visual acuity according to the angiographic subtype, visual acuity, and lesion size at baseline, respectively. In relation to the visualization of choroidal new vessels (classic) in the fluorescein angiogram, a predominantly classic lesion includes 50 percent or more classic choroidal neovascularization, a minimally classic lesion includes less than 50 percent classic choroidal neovascularization, and an occult lesion includes no classic choroidal neovascularization. For lesion size, the unit of measurement was one optic-disk area, equal to 2.54 mm^2 . For this analysis, lesions were categorized as less than four optic-disk areas or four or more optic-disk areas in size. In Panels B, C, and D, the asterisk denotes $P < 0.05$ for the comparison of pegaptanib with sham injection, the single dagger $P < 0.001$ for the comparison of pegaptanib with sham injection, and the double dagger $P < 0.01$ for the comparison of pegaptanib with sham injection. Of a total of 1186 patients, 294 received 0.3 mg of pegaptanib, 300 received 1.0 mg of pegaptanib, 296 received 3.0 mg of pegaptanib, and 296 received sham injection.



of use of photodynamic therapy among patients receiving sham injections.

On the two angiographic examinations, there was a slowing in the growth of the total area of a lesion, the size of choroidal neovascularization, and the severity of leakage in the groups receiving pegaptanib as compared with the sham-injection group (Table 4). A difference was evident at weeks 30 and 54.

The rate of discontinuation of therapy due to adverse events was 1 percent in the pegaptanib groups and 1 percent in the sham-injection group. The reasons for discontinuation were diverse and were not clustered in relation to a particular system or organ. No systemic adverse events were definitively attributed by the independent data management and safety monitoring committee to the study drug, nor were any observed for any organ system in all three treatment groups. In a comparison of rates of adverse events (for all doses of pegaptanib as compared with sham injection), no significant difference was observed in the rates of vascular hypertensive disorders (10 percent in all groups); hemorrhagic adverse events (2 percent and 3 percent, respectively); thromboembolic events (6 percent in all groups), and gastrointestinal perforations (0 in all groups). The baseline laboratory values were

similar in all groups, and median changes in all laboratory values from baseline were small and not clinically meaningful. The death rate was 2 percent in all groups, which is similar to that seen in other studies of age-related macular degeneration in this population.²¹ No antibodies against pegaptanib were detected. There were also no reports of local or systemic hypersensitivity attributable to pegaptanib.

Most adverse events reported in the study eyes were transient, with a severity that was mild to moderate, and were attributed by the investigators to the injection procedure, rather than to the study drug. Common ocular adverse events that occurred more frequently in the study eyes of patients treated with pegaptanib than in those receiving sham injection were eye pain (34 percent vs. 28 percent), vitreous floaters (33 percent vs. 8 percent, $P < 0.001$), punctate keratitis (32 percent vs. 27 percent), cataracts (20 percent vs. 18 percent), vitreous opacities (18 percent vs. 10 percent, $P < 0.001$), anterior-chamber inflammation (14 percent vs. 6 percent, $P = 0.001$), visual disturbance (13 percent vs. 11 percent), eye discharge (9 percent vs. 8 percent), and corneal edema (10 percent vs. 7 percent).

These events were more common in the study eyes than in the other eyes among patients in the sham-injection group, suggesting that the events were in part a result of the preparation procedure for injection, as opposed to the study drug. There was no evidence of a sustained elevation in intraocular pressure or of an acceleration of the formation of a cataract among patients in the treatment groups as compared with those in the sham-injection group. A masked review by the reading center at the University of Wisconsin of all angiograms obtained at baseline and at weeks 30 and 54 revealed no evidence of adverse effects on the retinal or the choroidal vascular beds.

Injection-related adverse events are summarized in Table 5. Endophthalmitis, a potentially serious intraocular infection that may result in the loss of visual acuity, is thought possibly to result from the intravitreal route of administration. Of the 12 patients (1.3 percent of 890 receiving pegaptanib) in whom endophthalmitis developed over the period of 54 weeks, 1 patient (0.1 percent of all treated patients, and 8 percent of those with endophthalmitis) had a loss of 30 letters or more of visual acuity (i.e., visual acuity decreased from 20/63 at baseline to 20/800 at the last patient visit) in association with the infection. Two thirds of the patients with en-

Table 4. Changes in Size of Lesion, Extent of Choroidal Neovascularization (CNV), and Leakage over Time in 1186 Patients.

Variable*	0.3 mg Pegaptanib (N=294)	1.0 mg Pegaptanib (N=300)	3.0 mg Pegaptanib (N=296)	Sham Injection (N=296)
Total size of lesion				
Baseline	3.7	4.0	3.7	4.2
Wk 30	4.9	5.0	5.2	5.7
Wk 54	5.5†	5.8†	6.2	6.7
Total size of CNV				
Baseline	3.1	3.5	3.2	3.7
Wk 30	4.0	4.2	4.2	4.9
Wk 54	4.7	4.7†	5.0	5.8
Total size of leakage				
Baseline	3.3	3.4	3.4	3.6
Wk 30	4.0†	3.6†	4.2	4.9
Wk 54	4.3	3.9†	4.6	5.2

* The total size of a lesion, choroidal neovascularization, or leakage was measured as the number of optic-disk areas, each of which is equal to 2.54 mm².
† $P < 0.01$ for the comparison of the change from baseline with that in the sham-injection group.

dophthalmitis had a positive culture. Coagulase-negative *Staphylococcus epidermiditis* was the most common isolate. All patients with clinical endophthalmitis were treated with intravitreal antibiotics. In 8 of the 12 patients with endophthalmitis (67 percent), the infection was associated with protocol violations, the most common being failure to use an eyelid speculum, an instrument that prevents the bacteria on the eyelashes from contaminating the injection site.

DISCUSSION

Pegaptanib produced a statistically significant and clinically meaningful benefit in the treatment of neovascular age-related macular degeneration. Overall, a reduced risk of visual-acuity loss was observed with all doses as early as six weeks after treatment was begun, with evidence of an increasing benefit over time up to week 54 (Fig. 1A). This observation was supported by a variety of findings. Pegaptanib reduced the chance not only of the loss of 15 letters or more of visual acuity (considered a moderate loss), but also of a loss of 30 letters or more (six lines on the study eye chart, which is considered a severe loss). In addition, treatment with pegaptanib reduced the risk of progression to legal blindness in the study eye, promoted stability of vision, and in a small percentage of the patients, resulted in more visual improvement at week 54 than among those receiving sham injections.

The visual results are further supported by angiographic measurements obtained by personnel masked to the treatment assignments, which suggested a reduction in the growth of the total size of the lesion or of choroidal neovascularization and in the severity of leakage (Table 4). These data provide indirect biologic evidence of the mechanism of action of pegaptanib. Although fluorescein angiography is a time-honored method of assessing neovascular age-related macular degeneration, the quantitative measurements of the size of a lesion and of choroidal neovascularization may have been confounded by changes in permeability that accompanied pegaptanib therapy. Any conclusions about the extent of choroidal neovascularization and lesion size must be made, therefore, with this caveat in mind. The inhibition of permeability by pegaptanib may have played an important role in the visual outcomes observed. A reduction in vascular permeability probably accounted for the improved outcome at six weeks, because the data indicate

there was little likelihood of a meaningful change in choroidal neovascularization or lesion size at that point.

Because all forms of choroidal neovascularization have been associated with elevated levels of VEGF, it was hypothesized that a broad spectrum of patients might benefit from anti-VEGF therapy with pegaptanib. Indeed, there was no evidence that any one baseline characteristic, including angiographic subtype, lesion size, or initial level of visual acuity, precluded a treatment benefit. The beneficial responses observed with pegaptanib probably imply that a common underlying disease process was treated. These data support the hypothesis that pegaptanib is effective in a broad population of patients with neovascular age-related macular degeneration. Since approximately 90 percent of the patients enrolled completed the two trials, the intravitreal-injection regimen also appeared to be accepted by both patients and physicians.

The per-injection rates of endophthalmitis (0.16 percent), retinal detachment (0.08 percent), and traumatic lens injury (0.07 percent) in the current trial were similar to rates identified in a comprehensive review of more than 15,000 intravitreal injections.²² Therefore, the risks associated with intraocular injection of pegaptanib are probably no different from those associated with intraocular injection of other drugs. Because this treatment requires multiple injections, the risk of endophthalmitis was 1.3 percent per patient during the first year of the trials. For comparison, the range of the reported risk of endophthalmitis associated with cat-

Table 5. Injection-Related Adverse Events in 890 Patients Treated with Pegaptanib in the First Year of the Trial.*

Adverse Event	Events		Severe Loss of Visual Acuity†
	no. of patients (%)	per injection (%)	no. of patients (%)
Endophthalmitis	12 (1.3)‡	0.16	1 (0.1)
Traumatic injury to the lens	5 (0.6)	0.07	1 (0.1)
Retinal detachment	6 (0.7)	0.08	0§

* A total of 7545 intravitreal injections of pegaptanib were administered.

† Severe loss of visual acuity is defined as a loss of 30 letters or more.

‡ Three quarters of the patients with endophthalmitis remained in the trial; among the patients with endophthalmitis, the condition was associated with protocol violations in two thirds.

§ Measurements of visual acuity after the event were not available for one patient.

aract surgery is 0.06 percent to 0.4 percent. Our data show that, despite this risk, the majority of patients fare better with eight to nine injections over the course of a year than with no treatment. However, in order to maximize the benefit of treatment, it is critical that all treating ophthalmologists carefully adhere to an appropriate aseptic technique for each injection, educate patients regarding worrisome symptoms, and closely monitor patients after each injection. Careful attention to the technique of the procedure can probably minimize the risk of endophthalmitis after intravitreal injection.²³

For ethical reasons, sham injection was used as a control in these studies. Preclinical experiments have shown that it is unlikely that control intravitreal injections would have resulted in a visual improvement. Endogenous VEGF-induced retinal vascular permeability in a rat model was not inhibited when phosphate-buffered saline or an inactive control (e.g., polyethylene glycol) was given by intravitreal injection. Only intravitreal injections of pegaptanib reduced vascular permeability.²⁴ Similarly, studies in primates have shown that intravitreal injections of a VEGF inhibitor effectively suppressed neovascularization in the iris and the choroid, whereas intravitreal injections of inac-

tive control substances such as phosphate-buffered saline or nonimmune antibody did not appear to alter the natural course of the disease.^{6,8}

In summary, treatment with pegaptanib provided a statistically significant and clinically meaningful benefit in a broad spectrum of patients with neovascular age-related macular degeneration, regardless of the size or angiographic subtype of the lesion or the baseline visual acuity. The rate of injection-related adverse events represents a potentially modifiable risk but necessitates vigilance. Because age-related macular degeneration tends to progress over years, long-term data will be required for a full characterization of the safety and efficacy of pegaptanib therapy. Our results provide validation of aptamer-based therapy in the treatment of human disease and support ongoing investigations into the use of VEGF antagonists in patients with diabetic retinopathy and retinal-vein occlusion, which are other disorders associated with elevated levels of intraocular VEGF.

Supported by Eyetech Pharmaceuticals and Pfizer.

Dr. Gragoudas reports having served as a paid consultant for Eyetech Pharmaceuticals and Neovista and receiving royalty income from Coherent, the manufacturer of a laser used in photodynamic therapy; Drs. Adamis, Cunningham, Guyer, and Feinsod are employees of and shareholders in Eyetech Pharmaceuticals.

We are indebted to the patients who volunteered for this study.

APPENDIX

The following investigators, data managers, and research coordinators participated in the VEGF Inhibition Study in Ocular Neovascularization (V.I.S.I.O.N.) Clinical Trial Group study: Writing Committee — E.S. Gragoudas (chair and corresponding author), A.P. Adamis, E.T. Cunningham, Jr., D.R. Guyer, M. Feinsod; Steering Committee — M. Blumenkranz, Stanford University; M. Buyse, International Drug Development Institute; M. Goldberg, Johns Hopkins University; E.S. Gragoudas, J. Miller, Massachusetts Eye and Ear Infirmary; S.D. Schwartz, University of California at Los Angeles; L. Singerman, Retina Associates of Cleveland; L. Yannuzzi, Columbia University; A.P. Adamis, D.R. Guyer, D. O'Shaughnessy, Eyetech Pharmaceuticals; Independent Data Management and Safety Monitoring Committee — A. Bird, Moorfields Eye Hospital (chair); D. D'Amico, Massachusetts Eye and Ear Infirmary (chair emeritus); J. Herson; R. Klein, University of Wisconsin; H. Lincoff, New York–Presbyterian Weill Cornell Center; A. Patz, Wilmer Eye Institute; Data Management and Statistics Group — M. Buyse, S. de Gronckel, G. Fesneau, E. Quinaux, D. Tremolet, K. Wang, International Drug Development Institute, Brussels and Boston; A. Brailey, J. Finman, N. Ting, Pfizer, Groton, Conn.; Eligibility and Classification Quality Assurance Team — N.M. Bressler, S.B. Bressler, R. Denblow, O.D. Schein, S. Seabrook, S. Solomon, A.P. Schachat, D. Philips, Wilmer Ophthalmological Institute, Johns Hopkins University; Independent Fundus Photograph and Angiogram Reading Center — M. Altaweel, M.D. Davis, B.A. Blodi, R.P. Danis, M.S. Ip, C. Hiner, J. Elledge, M. Webster, C. Hannan, J. Ficken, S. Alexander, M. Neider, H. Wabers, P. Vargo, E. Lambert, L. Kastorff, A. Carr, A. Shkiele, J. Baliker, University of Wisconsin, Madison; the V.I.S.I.O.N. Clinical Trial Group — R. Guymer, S. Quereschi, Centre for Eye Research Australia, East Melbourne, Australia; I. Constable, Lions Eye Institute, Nedlands, Australia; J. Arnold, S. Sarks, Marsden Eye Specialists, Parramatta, Australia; A. Chang, Eye and Vision Research Institute, Sydney; M. Gillies, Save Sight Institute, Sydney; P. Mitchell, Westmead Hospital, Westmead, Australia; A. Haas, Universitäts Augenklinik, Graz, Austria; M. Stur, Augenklinik Abt. Vienna; A. Leys, UZ St. Raphaël, Leuven, Belgium; C. Moreira, E. Portella, Hospital de Olhos do Paraná, Curitiba, Brazil; M. de Avila, A.C. Taleb, Universidade Federal de Goiás, Goiânia, Brazil; J. Lavinsky, Hospital das Clínicas de Porto Alegre, Porto Alegre, Brazil; M.E. Farah, Universidade Federal de São Paulo, São Paulo; G. Williams, Calgary Retina Consultants, Calgary, Alta., Canada; B. Leonard, University of Ottawa Eye Institute, Ottawa; R. Garcia, Eye Centre Pasqua Hospital, Regina, Sask., Canada; D. Maberley, Vancouver Hospital and Health Sciences Center, University of British Columbia Eye Care Center, Vancouver, Canada; J.M. Lopez, Pontificia Universidad Católica de Chile, Santiago, Chile; F. Rodriguez, Fundación Oftalmologica Nacional, Bogotá, Colombia; I. Fiser, Vinohrady Teaching Hospital, Prague, Czech Republic; M. Larsen, Herlev Hospital, Herlev, Denmark; J.-F. Korobelnik, Groupe Hospitalier Pellegrin, Bordeaux, France; G. Soubbrane, Hospitalier Universitaire de Creteil, Creteil, France; F. Koenig, Centre de Recherche en Ophtalmologie, Lyon, France; A. Gaudric, Hopital Lariboisiere, Paris; S. Dithmar, F.G. Holz, University of Heidelberg, Heidelberg, Germany; A. Joussen, B. Kirchhof, University of Cologne, Cologne, Germany; P. Wiedemann, Universitätsklinikum Leipzig Klinik und Poliklinik, Leipzig, Germany; D. Pauleikhoff, St. Franziskus Hospital, Muenster, Germany; U. Schneider, University Eye Clinic Tübingen, Tübingen, Germany; I. Suveges, Semmelweis University, Budapest, Hungary; J. Gyory, Csolnoky Ferenc County Hospital, Kórház, Hungary; A. Pollack, Kaplan Medical Center, Rehovot, Israel; A. Loewenstein, Ichilov Medical Center, Tel Aviv, Israel; I. Rosenblatt, Rabin Medical Center, Tikva, Israel; A. Giovannini, Istituto di Scienze Oftalmologiche, Ancona, Italy; U. Menchini, II Clinica Oculistica Università degli Studi di Firenze, Firenze, Italy; R. Brancato, Universitario Ospedale San Raffaele,

Milan, Italy; F. Cardillo Piccolino, F.M. Grignolo, Università di Torino, Turin, Italy; F. Bandello, Policlinico Universitario, Udine, Italy; R. Schlingemann, AMC University of Amsterdam, Amsterdam; A. Deutman, UMC St. Radboud, Institute of Ophthalmology, Nijmegen, the Netherlands; J. Kaluzny, Akademia Medyczna ul M. Skłodowskiej-Curie, Bydgoszcz, Poland; K. Pecold, Akademia Medyczna ul. Długa, Poznań, Poland; J. Cunha-Vaz, R. da Silva, Associação Para Investigação Biomedica e Inovação Em Luz e Imagem, Universidade de Coimbra, Coimbra, Portugal; J.M. Ruiz Moreno, VISSUM-Instituto Oftalmologico de Alicante, Alicante, Spain; J. Mones, Instituto de Microcirugia Ocular, Barcelona, Spain; M. Figueroa, Hospital Oftalmologico Internacional, Madrid; C. Pournaras, Hoptal Cantonal de Geneva, Geneva; L. Zografos, Hoptal Ophthalmique Jules Gonin, Lausanne, Switzerland; N. Lois, Aberdeen Royal Infirmary, Aberdeen, United Kingdom; U. Chakravarthy, Queen's University Belfast Royal Victoria Hospital, Belfast, United Kingdom; P. Hykin, Moorfields Eye Hospital, London; I. Chisholm, Southampton General Hospital, Southampton, United Kingdom; M.W. Johnson, W.K. Kellogg Eye Center, Ann Arbor, Mich.; D. Marcus, Medical College of Georgia, Augusta; N. Mandava, Rocky Mountain Lion Eye Institute, Aurora, Ill.; J. Haller, Wilmer Eye Institute, Baltimore; F. Cangemi, Vitreo-Retinal Associates of New Jersey, Belleville; D. Boyer, Retina Vitreous Associates, Beverly Hills, Calif.; J. Arroyo, J. Lowenstein, Massachusetts Eye and Ear Infirmary, Boston; J. Heier, Ophthalmic Consultants of Boston, Boston; E. Reichel, New England Eye Center, Boston; P.M. Falcone, Connecticut Retina Consultants, Bridgeport; D.J. Weissgold, University of Vermont College of Medicine, Burlington; B.P. Conway, University of Virginia, Charlottesville; R. Garfinkel, Retina Group of Washington, Chevy Chase, Md.; B. Glaser, Glaser Murphy Retina Treatment Centers, Chevy Chase, Md.; A.T. Lyon, D. Weinberg, Northwestern University Sorrel Rosin Eye Center, Chicago; H. Lewis, Cleveland Clinic Cole Eye Institute, Cleveland; J.A. Wells, Palmetto Retina Center, Columbia, S.C.; L. Wilcox, Eye Center of Concord, Concord, N.H.; G. Fish, Texas Retina Associates, Dallas; D. Eliot, Kresge Eye Institute, Detroit; S. Fekrat, Duke University Eye Center, Durham, N.C.; B. Taney, Retina Vitreous Consultants, Fort Lauderdale, Fla.; A.M. Eaton, Retina Health Center, Fort Myers, Fla.; V. Deramo, S. Harrison, L.L. Vitreo-Retinal Consultants, Great Neck, N.Y.; J. Wroblewski, Cumberland Valley Retina Center, Hagerstown, Md.; D. Tom, New England Retina Associates, Hamden, Conn.; D.H. Chow, Illinois Retina Associates, Harvey; E. Holz, W. Mieler, Baylor College of Medicine, Houston; B. Kuppermann, University of California, Irvine; N. Sabates, Eye Foundation of Kansas City, Kansas City, Mo.; H. Cummings, Southeastern Retina Associates, Knoxville, Tenn.; S.D. Pendergast, Retina Associates of Cleveland, Lakewood, Ohio; C. Gonzales, Jules Stein Eye Institute, Los Angeles; J. Lim, Doheny Eye Institute, Los Angeles; S. Charles, Charles Retina Institute, Memphis, Tenn.; S. Sanislo, Stanford University School of Medicine, Menlo Park, Calif.; P. Rosenfeld, Bascom Palmer Eye Institute, Miami; T. Connor, Eye Institute, Milwaukee; H. Cantrill, VitreoRetinal Surgery, Minneapolis; R.D. Ross; R. Willson, Foundation for Retinal Research, New Orleans; K. Bailey-Freund, Manhattan Eye, Ear & Throat Retinal Research Office, New York; R. Rosen, New York Eye and Ear Infirmary, New York; R. Leonard, S. Nanda, Dean A. McGee Eye Institute, Oklahoma City; A. Brucker, Scheie Eye Institute, Philadelphia; A. Ho, Wills Eye Hospital Retina Research, Philadelphia; S. Sneed, Retinal Consultants of Arizona, Phoenix; T. Friberg, Eye and Ear Institute, Pittsburgh; M. Klein, Casey Eye Institute, Portland, Oreg.; P. Tornambe, Retina Consultants, Poway, Calif.; G. Stoller, Ophthalmic Consultants of Long Island, Rockville Centre, N.Y.; A. Capone, Associated Retinal Consultants, Royal Oak, Mich.; P. Bernstein, John Moran Eye Center, University of Utah, Salt Lake City; H.R. McDonald, H. Schatz, R.N. Johnson, West Coast Retina Medical Group, San Francisco; M. Nanda, Orange County Retina, Santa Ana, Calif.; R. Avery, California Retina Consultants, Santa Barbara; K. Wong, Sarasota Retina Institute, Sarasota, Fla.; W.S. Grizzard, Retina Associates of Florida, Tampa; P. Higgins, Retina Associates of New Jersey, Teaneck; H. Hudson, L. Joffe, Retina Associates, Tucson, Ariz.; M. Varenhorst, Vitreo-Retinal Consultants and Surgeons, Wichita, Kans.; M.M. Slusher, Wake Forest University Eye Center, Winston-Salem, N.C.; A.P. Adamis, F. Betts, E.T. Cunningham, Jr., K. Curtiss, M. Feinsod, D. Guyer, E. Harrison, H. Masonson, D. O'Shaughnessy, Eyetech Pharmaceuticals, New York; C. Beals, D. Eveleth, K. Ludwig, M. Patel, Pfizer, New York.

REFERENCES

1. Folkman J. Tumor angiogenesis: therapeutic implications. *N Engl J Med* 1971;285:1182-6.
2. Adamis AP, Miller JW, Bernal M-T, et al. Increased vascular endothelial growth factor levels in the vitreous of eyes with proliferative diabetic retinopathy. *Am J Ophthalmol* 1994;118:445-50.
3. Aiello LP, Avery RL, Arrigg PG, et al. Vascular endothelial growth factor in ocular fluid of patients with diabetic retinopathy and other retinal disorders. *N Engl J Med* 1994;331:1480-7.
4. Malecaze F, Clamens S, Simorre-Pinatel V, et al. Detection of vascular endothelial growth factor messenger RNA and vascular endothelial growth factor-like activity in proliferative diabetic retinopathy. *Arch Ophthalmol* 1994;112:1476-82.
5. Amano S, Rohan R, Kuroki M, Tolentino M, Adamis AP. Requirement for vascular endothelial growth factor in wound- and inflammation-related corneal neovascularization. *Invest Ophthalmol Vis Sci* 1998;39:18-22.
6. Adamis AP, Shima DT, Tolentino MJ, et al. Inhibition of vascular endothelial growth factor prevents retinal ischemia-associated iris neovascularization in a nonhuman primate. *Arch Ophthalmol* 1996;114:66-71.
7. Aiello LP, Pierce EA, Foley ED, et al. Suppression of retinal neovascularization in vivo by inhibition of vascular endothelial growth factor (VEGF) using soluble VEGF-receptor chimeric proteins. *Proc Natl Acad Sci U S A* 1995;92:10457-61.
8. Krzystolik MG, Afshari MA, Adamis AP, et al. Prevention of experimental choroidal neovascularization with intravitreal anti-vascular endothelial growth factor antibody fragment. *Arch Ophthalmol* 2002;120:338-46.
9. Leung DW, Cachianes G, Kuang W-J, Goeddel DV, Ferrara N. Vascular endothelial growth factor is a secreted angiogenic mitogen. *Science* 1989;246:1306-9.
10. Tolentino MJ, McLeod DS, Taomoto M, Otsuji T, Adamis AP, Luty GA. Pathologic features of vascular endothelial growth factor-induced retinopathy in the nonhuman primate. *Am J Ophthalmol* 2002;133:373-85.
11. Tolentino MJ, Miller JW, Gragoudas ES, Chatzistefanou K, Ferrara N, Adamis AP. Vascular endothelial growth factor is sufficient to produce iris neovascularization and neovascular glaucoma in a nonhuman primate. *Arch Ophthalmol* 1996;114:964-70.
12. Schwesinger C, Yee C, Rohan RM, et al. Intrachoroidal neovascularization in transgenic mice overexpressing vascular endothelial growth factor in the retinal pigment epithelium. *Am J Pathol* 2001;158:1161-72.
13. Congdon N, O'Colmain B, Klaver CC, et al. Causes and prevalence of visual impairment among adults in the United States. *Arch Ophthalmol* 2004;122:477-85.
14. Ferris FL III, Fine SL, Hyman L. Age-related macular degeneration and blindness due to neovascular maculopathy. *Arch Ophthalmol* 1984;102:1640-2.
15. Bressler NM, Bressler SB, Congdon NG, et al. Potential public health impact of Age-Related Eye Disease Study results: AREDS report no. 11. *Arch Ophthalmol* 2003;121:1621-4.
16. Gass JD. Pathogenesis of disciform detachment of the neuroepithelium. *Am J Ophthalmol* 1967;63:Suppl:S1-S139.
17. Green WR. Histopathology of age-related macular degeneration. *Mol Vis* 1999;5:27-36.
18. Green WR, Enger C. Age-related macular degeneration histopathologic studies:

- the 1992 Lorenz E. Zimmerman Lecture. *Ophthalmology* 1993;100:1519-35.
19. Dong LM, Childs AL, Mangione CM, et al. Health- and vision-related quality of life among patients with choroidal neovascularization secondary to age-related macular degeneration at enrollment in randomized trials of submacular surgery: SST report no. 4. *Am J Ophthalmol* 2004;138:91-108.
20. Ruckman J, Green LS, Beeson J, et al. 2'-Fluoropyrimidine RNA-based aptamers to the 165-amino acid form of vascular endothelial growth factor (VEGF₁₆₅): inhibition of receptor binding and VEGF-induced vascular permeability through interactions requiring the exon 7-encoded domain. *J Biol Chem* 1998;273:20556-67.
21. Photodynamic therapy of subfoveal choroidal neovascularization in age-related macular degeneration with verteporfin: one-year results of 2 randomized clinical trials — TAP report. *Arch Ophthalmol* 1999; 117:1329-45.
22. Jager RD, Aiello LP, Patel SC, Cunningham ET Jr. Risks of intravitreal injection: a comprehensive review. *Retina* 2004;24: 676-98.
23. Aiello LP, Brucker AJ, Chang S, et al. Evolving guidelines for intravitreal injections. *Retina* 2004;24:Suppl:S3-S19.
24. Ishida S, Usui T, Yamashiro K, et al. VEGF164 is proinflammatory in the diabetic retina. *Invest Ophthalmol Vis Sci* 2003;44: 2155-62.

Copyright © 2004 Massachusetts Medical Society.

JOURNAL EDITORIAL FELLOW

The *Journal's* editorial office invites applications for a one-year research fellowship beginning in July 2005 from individuals at any stage of training. The editorial fellow will work on *Journal* projects and will participate in the day-to-day editorial activities of the *Journal* but is expected in addition to have his or her own independent projects. Please send curriculum vitae and research interests to the Editor-in-Chief, 10 Shattuck St., Boston, MA 02115 (fax, 617-739-9864), by January 15, 2005.